


**PRESENTING CLINICAL SIGNS**
**DATE**

11/3/22

History: Sternal murmur. Diagnosed with hyperthyroidism in 2019 and well-managed on methimazole. Presented last week for peritoneal effusion and hindlimb edema. Cytology showed a non-specific transudate. Radiographs show possible cardiomegaly. AUS WNL except for the effusion.

**PERFORMED BY:**
**ECHOCARDIOGRAPHIC FINDINGS**

2D, M-mode, and Doppler study.

Dr. Meredith Swart

**INTERPRETED BY**

 Keith Blass, DVM,  
 MS, DACVIM  
 (Cardiology)

Left atrial size is normal. The mitral valve appears normal, though very mild mitral regurgitation is present. Left ventricular wall thickness is normal. Left ventricular internal dimensions are normal. Left ventricular systolic function is normal. The aorta and aortic valve appear normal. There is mild right atrial dilation. Right ventricular dimensions are normal. The tricuspid valve leaflets are mildly thickened, and a moderate jet of tricuspid regurgitation is present. TR velocity does not suggest the presence of pulmonary hypertension. The pulmonary artery and pulmonic valve are normal. No shunting lesions are visualized. No pericardial effusion or cardiac masses are seen.

**PATIENT**

Curious Frazier

LA/Ao - 1.48  
 IVSd - 4.1 mm  
 LVPWd - 4.0 mm  
 LVIDd - 13.0 mm  
 LVIDs - 7.0 mm  
 FS - 46%  
 LVOT - 1.02 m/s  
 RVOT - 0.86 m/s  
 TR - 2.65 m/s

**SPECIES**

Feline

**ASSESSMENT/RECOMMENDATIONS**
**BREED**
**DSH**
**SEX**
**FS**
**AGE**

16 y

**WEIGHT**

6 lb

**HOSPITAL NAME**

 Swart Veterinary  
 Imaging

**REFERRING VET**

Dr. Swart

This examination demonstrates regurgitation of blood across Curious' mitral and tricuspid valves. Curious' mitral valve regurgitation is mild, and is well-compensated at this time. Her tricuspid valve regurgitation is more significant, and Curious has mild secondary dilation of her right atrium. Given the presence of mild right atrial dilation, it's possible that right-sided congestive heart failure could be the cause of Curious' peritoneal effusion and hindlimb edema, though a non-cardiac cause cannot be ruled out.

I recommend starting Curious on enalapril (1.25 mg BID) and clopidogrel (18.75 mg SID), as these medications should help to slow the progression of her right atrial dilation and decrease her risk for cardiac thrombus formation, respectively. I also recommend a trial with furosemide (3.125 mg BID) to see if Curious' effusion/edema could be the result of elevated hydrostatic pressure.

A recheck physical exam and renal/electrolyte profile are recommended in 1-2 weeks. A recheck echocardiogram is recommended in 6 months.



DATE

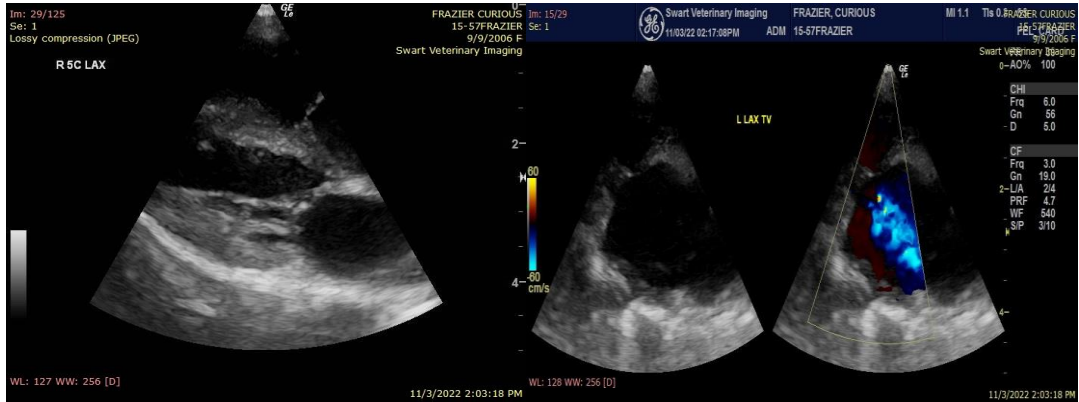
11/3/22

PERFORMED BY:

Dr. Meredith Swart

INTERPRETED BY

Keith Blass, DVM,  
MS, DACVIM  
(Cardiology)



PATIENT

Curious Frazier

The information and recommendations provided are based on the images presented by the referring veterinarian. No evaluation can be communicated regarding pathology that was not visible in the image/video clips provided.

Thank you for this referral. If the clinical or image interpretation does not parallel your findings or if I can be of any further assistance please contact me.

SPECIES

Feline

Keith Blass, DVM, MS, DACVIM (Cardiology)  
KeithBlass@gmail.com  
631-804-5754

BREED

DSH

SEX

FS

AGE

16 y

WEIGHT

6 lb

HOSPITAL NAME

Swart Veterinary  
Imaging

REFERRING VET

Dr. Swart